

# Macular Degeneration: The Inside Story

A public service of MD Support

## Part #1

These people have just enjoyed their dinner. They try to get together at least once a month in one of their homes.



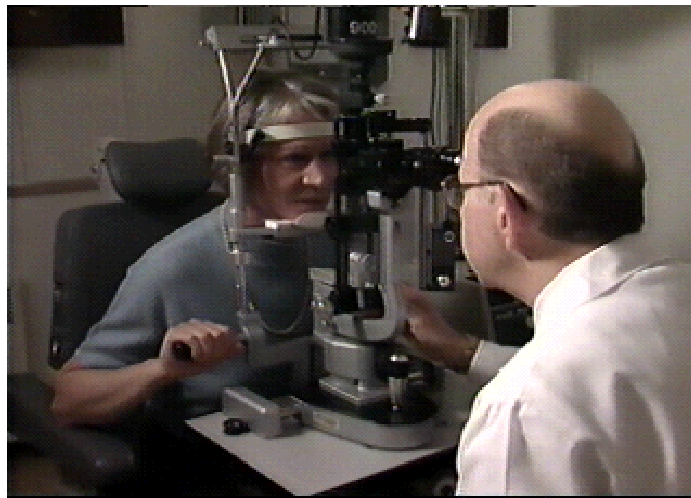
**Ann**, a school teacher, is the evening's hostess; **Dorothy** owns a small gift shop; and **Ruth** is a receptionist for an accounting office. **John**, a widower, is now retired after working for over forty years in sales.



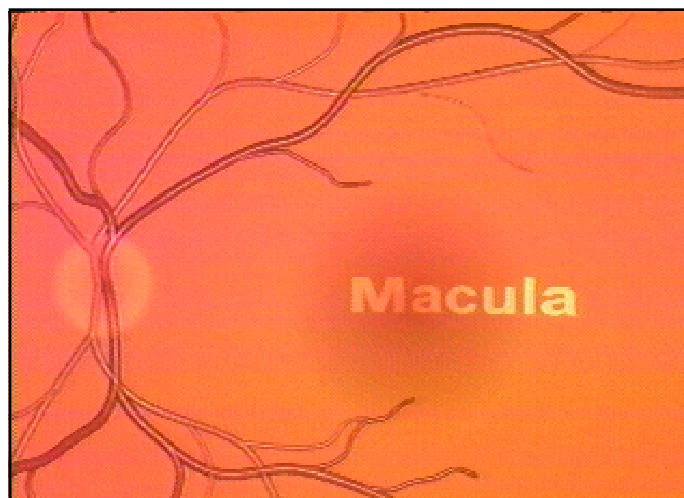
What do Ann, Dorothy, Ruth, and John have in common? All but one has **macular degeneration**, an eye disease that can cause partial or complete loss of central vision.

One of them can't identify faces or read fine print. Another sees curved door frames and bent telephone poles. Yet another needs only to shut one eye to make an entire bus seem to disappear from the highway. A casual observer would find it difficult to figure out which of them had vision problems, but a look into their eyes would quickly resolve the mystery.

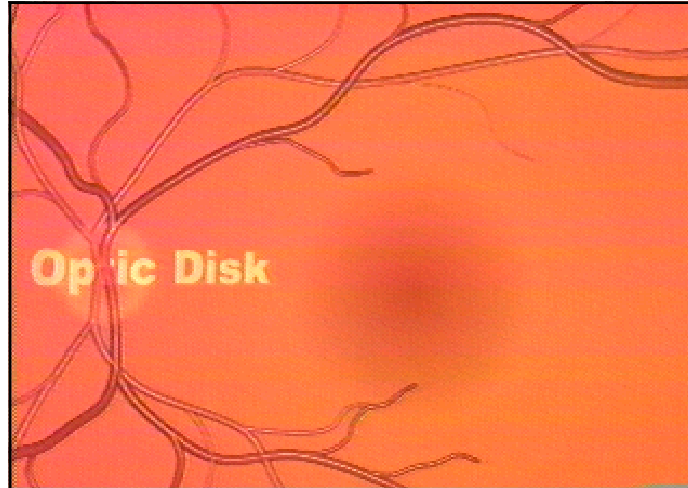
Eyes must be **dilated** before they can be examined properly. Eye drops are used to relax the muscles of a patient's iris, opening the pupil so that a doctor can view the retina, which lines the inside of the eyeball.



The retina captures light, just like the film in a camera. Film, however, is different, in that it is just as sensitive at its edge as in its center. Only the **center** of the retina, the area called the **macula**, can see fine detail.





**Photoreceptor cells** deep in the retina convert the light into electrical impulses. These impulses travel to the brain **through nerve fibers**. The nerve fibers exit the eyeball at the optic disk. They reach the brain through the optic nerve.





An examiner peering through the clear vitreous gel that fills much of the eye, actually looks through the transparent layers of the retina which include the **nerve fiber layer** (above) . . .

. . . **ganglion cells** . . .



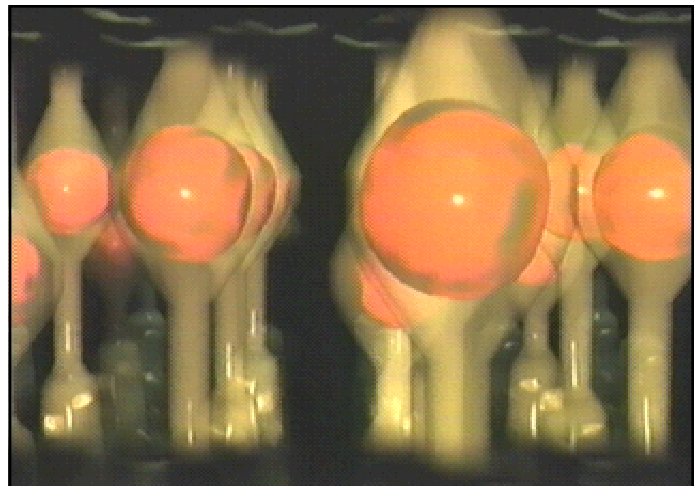
. . . the **inner plexiform layer** . . .

... bipolar and horizontal cells ...




... the outer plexiform layer ...

... the outer nuclear layer ...



... and finally, the **photoreceptors**.

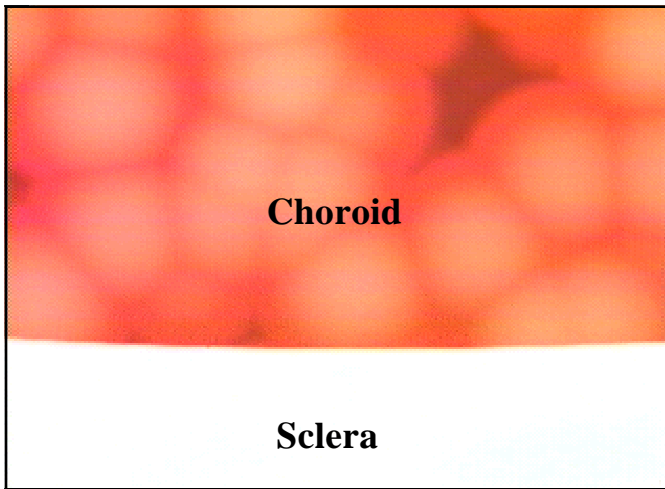



These transparent retinal layers lie on top of the retina's darkly pigmented layer, the **retinal pigment epithelium**, or RPE. The RPE supplies nutrients to the photoreceptors. The RPE is a single layer of cells.



**Bruch's membrane** is a thin tissue layer that separates the RPE from the underlying blood vessels of the **choroid**. Bruch's membrane is the dark layer at the bottom of the above photo.

The choroid lies  
between Bruch's membrane...



... and the eye's tough white  
outer shell, known as the **sclera**.

**End part 1 of 3**

**Use your back button to return to the link for part 2.**